

AABP FACT SHEET

ASSESSING A HERD HOOF-TRIMMING PROGRAM



Authored by
**THE AABP LAMENESS
COMMITTEE**

Introduction

The basic objectives of hoof-trimming are to balance the weight bearing between the inner and outer claws, correct the altered displacement of weight from heel to toe in overgrown claws, return the claws to normal shape and proportions, and to find and correct early lesions.

While it is true to say that a good hoof-trimming program is an essential component of lameness prevention, it is also equally true that lameness problems may result from poor trimming technique.

The majority of veterinarians have not been trained in hoof-trimming techniques formally, but they have a knowledge of anatomy and disease that should enable them to judge the quality of trimming on a farm and identify major problems. It is not the objective of this document to provide a 'how to' guide to trimming bovine feet, rather the aim is to point out some common trimming errors that do cattle harm if not prevented.

Trimming Capacity

Current evidence suggests that the benefits of restoring hoof balance after routine functional claw trimming last the average cow approximately 4 months. It is not unreasonable to recommend therefore, that cows should be trimmed at least twice per lactation, usually around the time of dry-off and around 70-150 days in milk. Some cows with poor hoof conformation require more frequent trimming (for example every 60-90 days) and cows with prolonged lactations should be trimmed

again prior to dry-off. There are also benefits in some herds to trimming maiden heifers prior to calving, provided that the job is done by a skilled trimmer. It is also common in North America for the majority of lame cows to be treated by the hoof-trimmer at one of the routine visits.

It is useful to calculate the expected number of cow-trims per year. For a typical 1000 cow dairy, trimming twice per lactation, with a lameness incidence of 45 cow cases per 100 cows per year, the expected number of trims would therefore be approximately; $(1000 \times 2) + (45 \times 1000/100) = 2450$ cow trims per year. If a trimmer serves 50 cows per visit, 49 $(2450/50)$ visits per year would be required, meaning that the herd should be visited weekly.

If the number of trims recorded is much less than the expected number, then it is clear that the hoof-trimming program described is not being adhered to. If the number is far in excess of the expected number, then the rate of lameness may be very high, or some cows maybe being trimmed too frequently due to chronic lameness. These cows need to be identified so that they are not continuously presented to the trimmer as a 'new case' of lameness each visit.

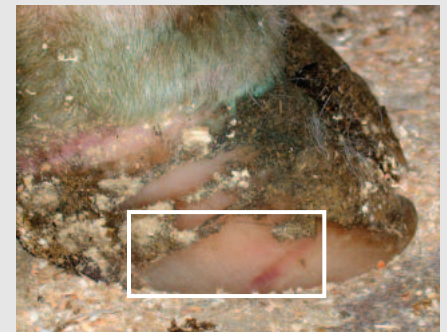
If the number of cows trimmed per day exceeds around 50-60, then the quality of work and the method of recruitment of cows for trimming should be examined. Trimmers that work too quickly may miss lesions, not apply hoof-blocks where needed and make more trimming errors.

Common Trimming Errors

1. Excessive removal of the abaxial wall of the hoof

This is a common problem seen where trimmers misuse grinders. While it is perfectly acceptable to round off the toe end of the claw, it is not acceptable to remove the side wall further back towards the heel. This practice is associated with an increased risk for white line disease development.

TEST: Examine the side wall of recently trimmed cattle. The claw side wall should be healthy and show faint horizontal ridges. It should not be pale in color and smooth, and there should be no evidence of grinder tracks.



AABP FACT SHEET

Assessing a Herd Hoof-trimming Program *continued*

2. Trimming the toes too short.

For the average sized mature Holstein cow, the dorsal hoof wall from a point approximately midway down the periople (with finger pressure - where the hard horn starts to grow) to the toe should measure a **minimum** of 3 inches (7.5 cm).

If the toe is trimmed too short, then the sole will be made too thin in the toe and the cow will be susceptible to white line fissure development in the axial and abaxial wall region of the toe.

TEST: Measure the dorsal claw wall using a 3 inch marker from the hard horn approximately midway down the periople to the toe. Identify claws that are too short.

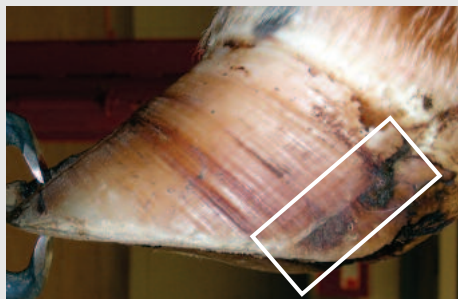


Note the length of the toe relative to a 3 inch marker. This claw is clearly too short.

3. Excessive trimming of the heel of the inner claw of the rear foot.

In intensively managed cattle living on concrete, it is common for the soles of the inner and outer claw to become excessively worn. A vital part of corrective hoof-trimming is to transfer weight from the heel of the outer claw to the inner claw. It is therefore important that trimmers preserve the height of the inner claw in situations of excessive wear.

TEST: When the length of the abaxial groove (the line on the side wall where the perioplic horn wraps around to join the horn of the wall) is equal to or less than 1.5 inches, the sole/heel of the weight bearing surface may give with digital pressure indicating that it is too thin. This may be due to wear or trimming. Therefore examine the inner claw heels of recently trimmed cattle. There should be no evidence of trimming caudal to the abaxial groove.

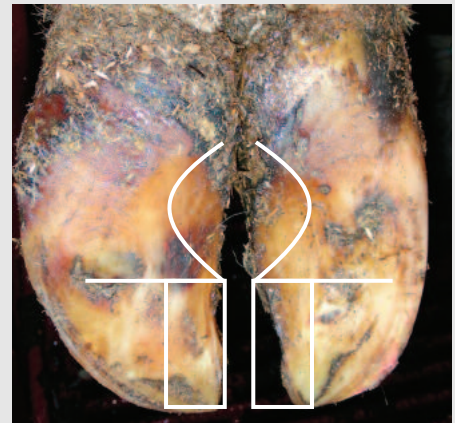


The abaxial groove (white box)—heel should not be trimmed caudal to the groove

4. Removal of the axial wall of the toe of the inner or outer claw.

The removal of horn from around the interdigital space from the inner and outer claw (modeling), should be confined to the area caudal to the axial groove, where the white line leaves the weight bearing surface. The axial wall at the toe is a weight bearing surface that should not be removed.

TEST: Observe the trimmer modeling the interdigital space and/or examine recently trimmed claws to make sure that the axial wall is intact.



Modeling the axial wall area should occur only above the horizontal lines demarcating the point where the axial wall white line leaves the bearing surface. In this foot, the axial wall has been removed near the toe in the areas demarcated by the white boxes.

AABP FACT SHEET

Assessing a Herd Hoof-trimming Program *continued*

5. Trimming the sole too thin.

The healthy sole should be at least 7 mm thick and not give under firm thumb pressure or reasonable pressure with hoof-testers. Thin soles will predispose the cow to white line fissures in the toe region, and toe ulcers.

TEST: Examine cows that have been trimmed recently and those that have not been trimmed for more than 4 months. Determine sole thickness before and after trimming to ascertain whether the problem is due to the environment, the trimmer, or a combination of the two. Consult treatment records for evidence of an increase in lesions located in the toe region of the claw.

6. Trimming the sole of claws with extreme concavity, rather than flat.

While pastured cattle develop overgrown wall horn and concavity of the sole, cows kept on concrete should not be trimmed with extreme concavity of the sole. When a cow stands on concrete with concave soles, the claws will be pushed apart, increasing weight transfer to the axial components of the inner and outer claw. This may predispose the claw to sole ulceration and hemorrhage in the typical site, below the flexor tuberosity of the third phalanx.

TEST: Examine recently trimmed claws and make sure that there is at least 0.75 inches of sole horn adjacent to the white line on the inner and outer claw that is trimmed per-

pendicular to the long axis of the limb, to provide claw stability.

7. Shortening of the toe without proper reduction of sole thickness

Overgrowth in the toe should be removed by shortening the toe and thinning the sole in the toe region to leave 5 mm (1/4 inch) of thickness at the cut end of the toe. However, a common error involves trimming the dorsal hoof wall down to shorten the toe, with minimal removal of sole horn. This does nothing to correct weight balance, and leaves the overgrown sole horn in the toe region of the claw.

TEST: The trimmer must be observed to detect this problem. They will typically use a grinder to thin the dorsal hoof wall down and avoid trimming the sole, but this technique must be differentiated from the trimming of corkscrew claws, where the dorsal wall curvature is corrected before the sole is trimmed.



Note the horn removed in the toe and the location of the white line. The overgrown sole has not been removed.

Use the 7-point check in this fact sheet to check on the hoof-trimming program. If problems are identified, discuss the issue with the trimmer and try to understand why cows are being treated incorrectly. Work with the trimmer to correct the issues and improve the hoof health of the animals in the herd. **AABP**